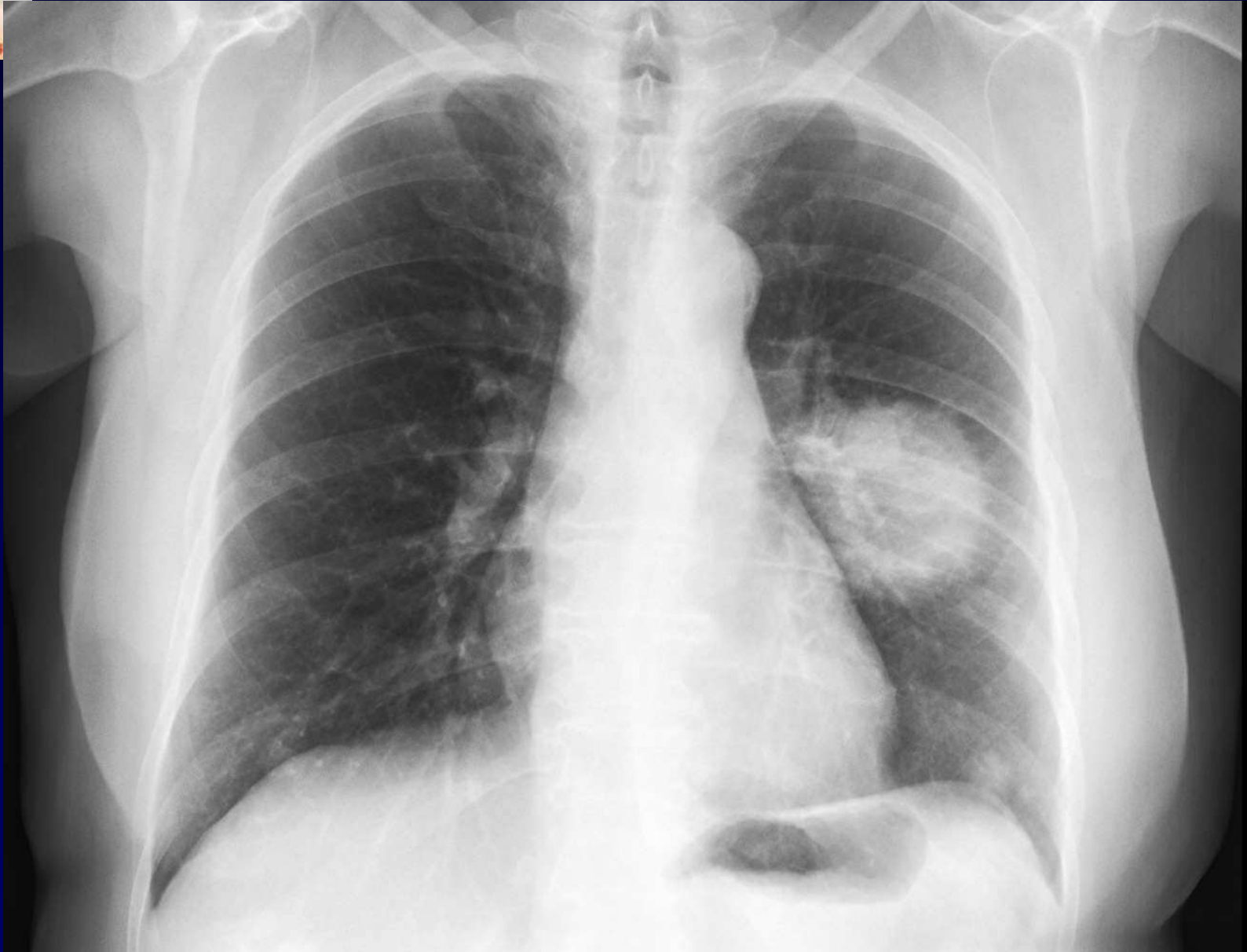
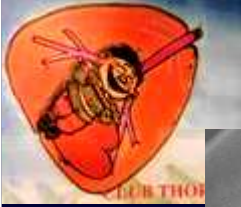


## **Dossier 1**

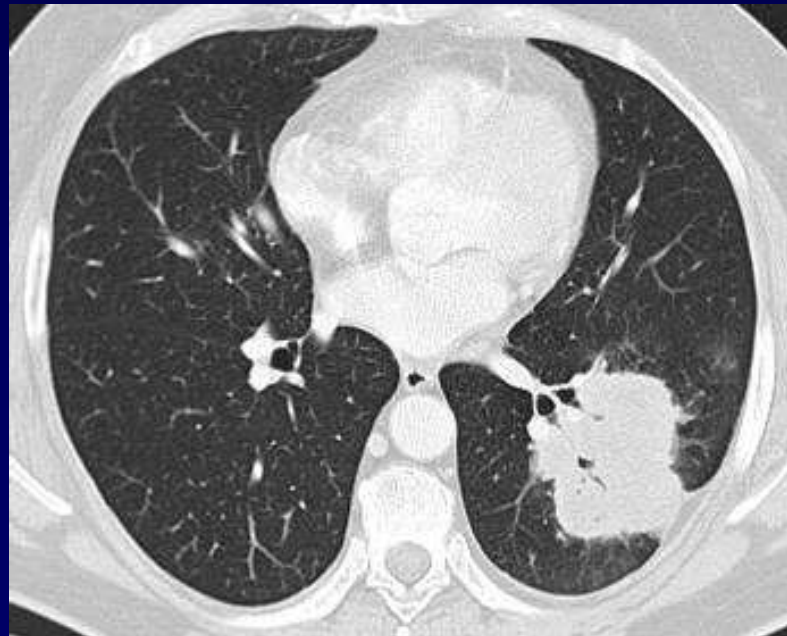
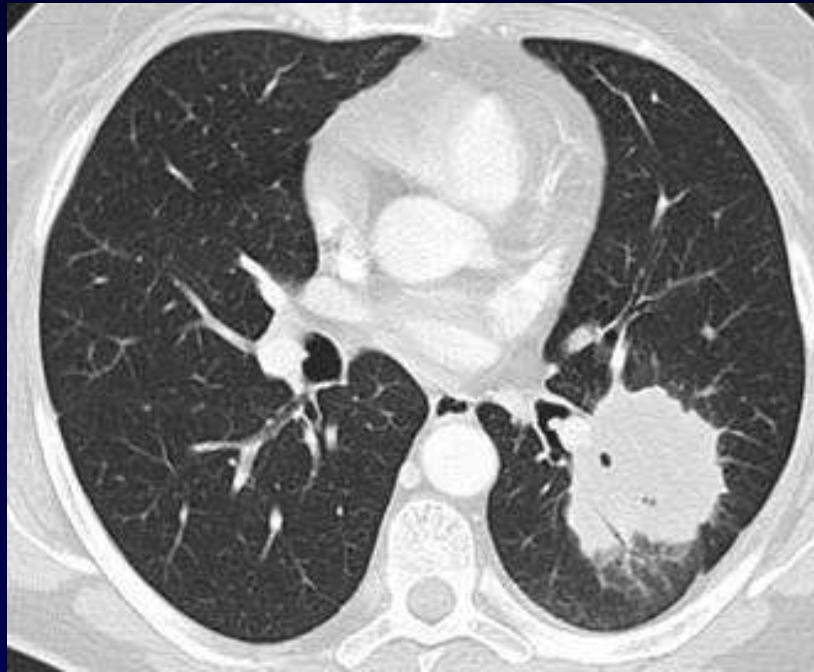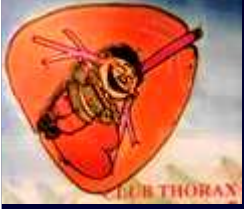**MP Debray**

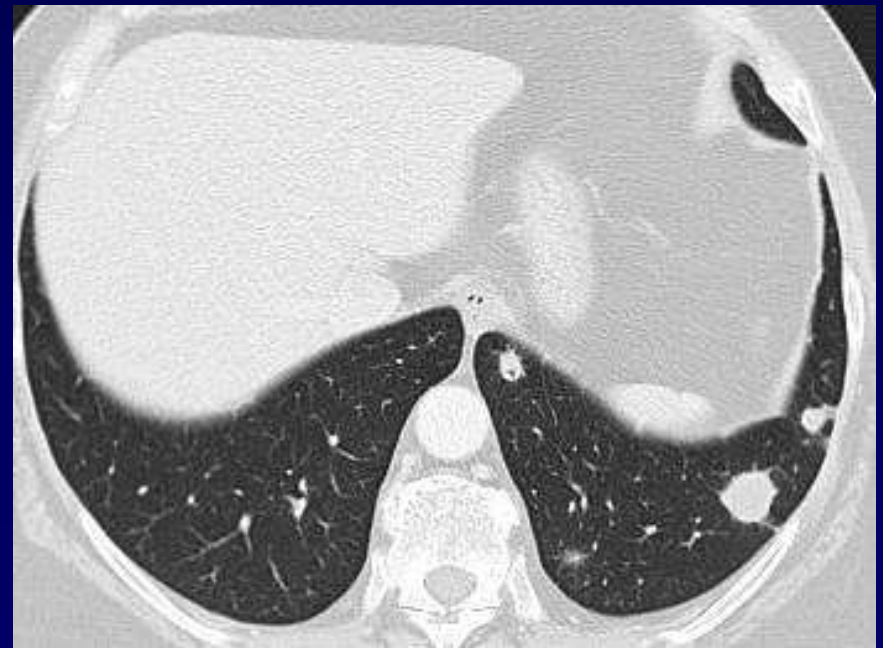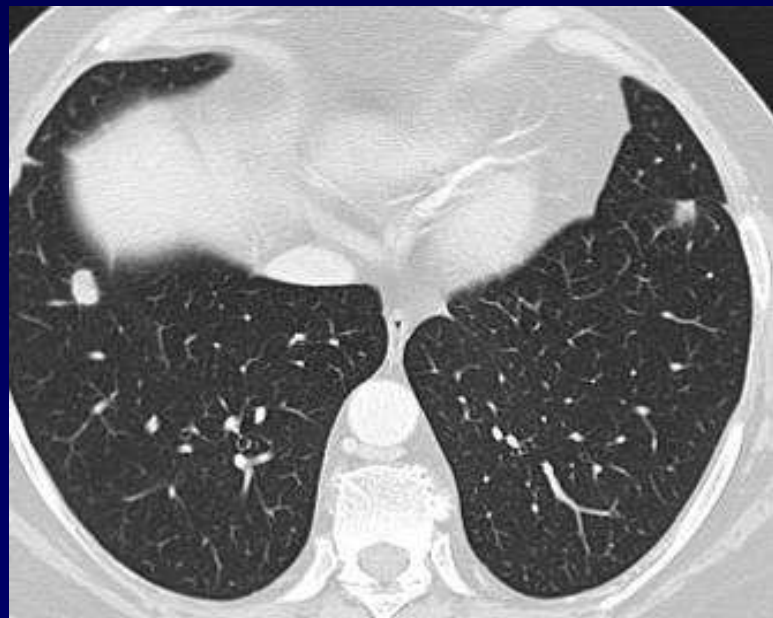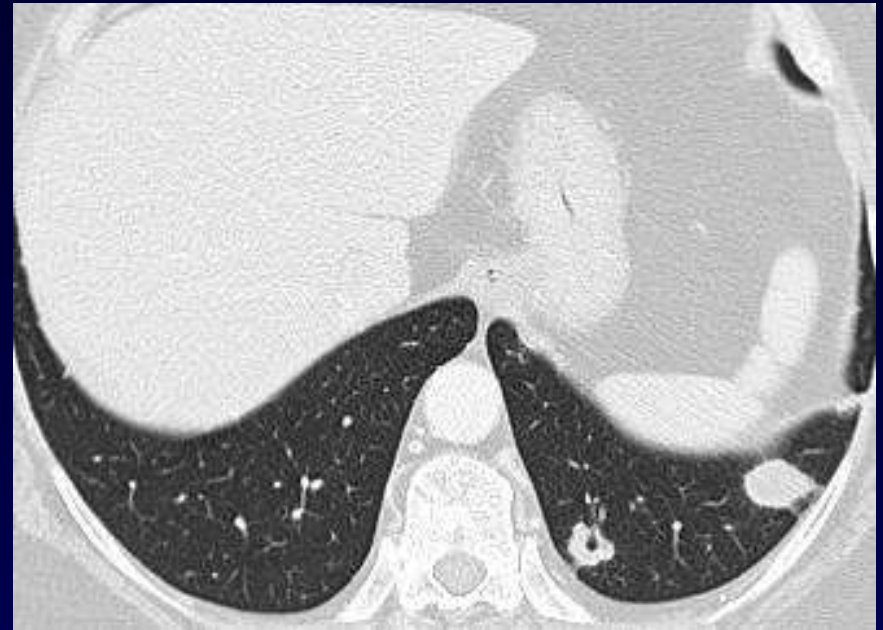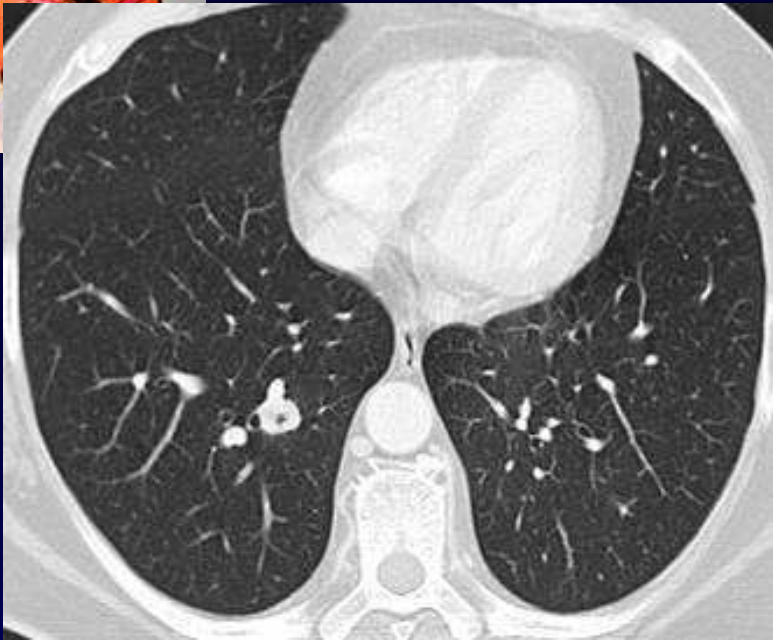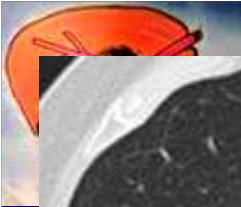
**Femme de 62 ans, tabagique,  
Amaigrissement  
Exacerbation d'un toux chronique  
Dysphonie  
3 nodules mammaires**

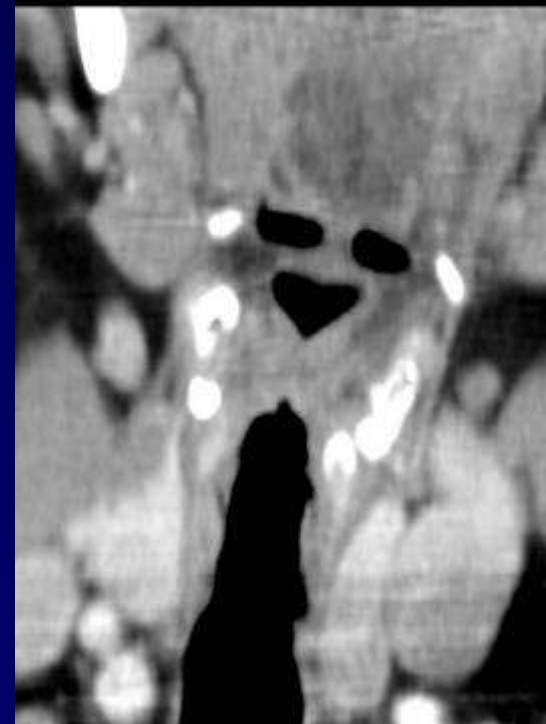
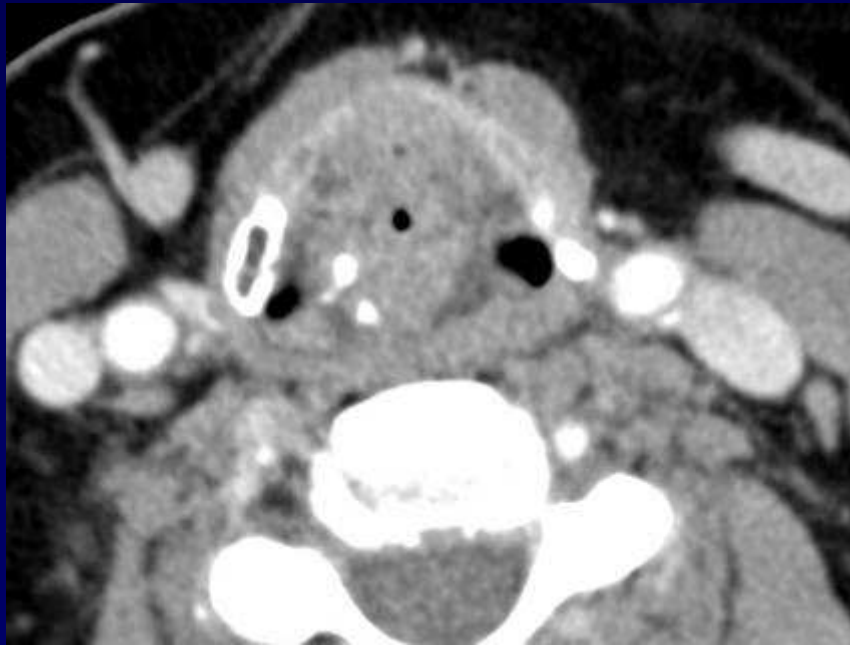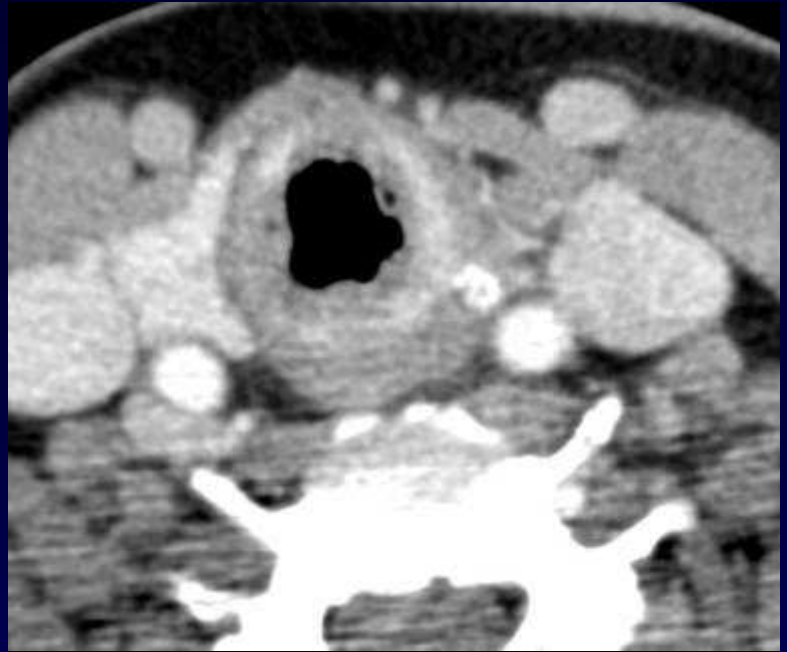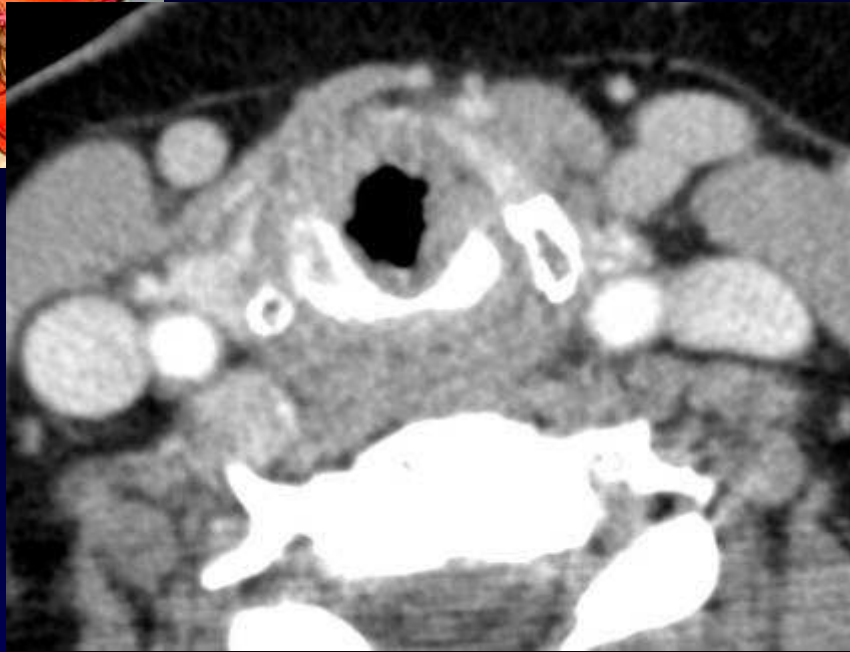
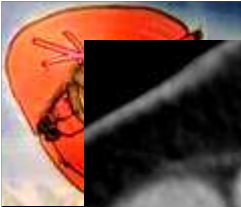




**Diagnostic ?**









**Diagnostic ?**



- **Biopsie mammaire**

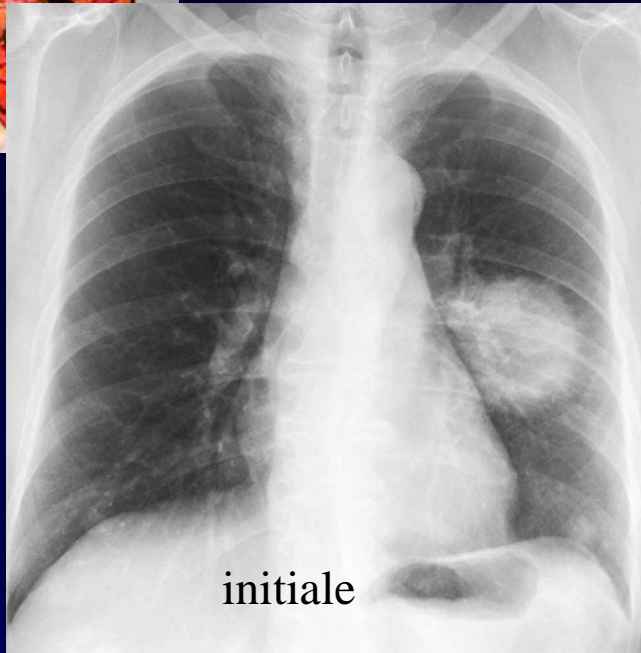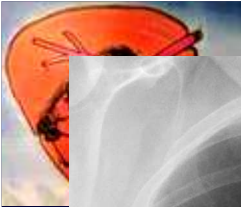Lésions de vascularite leucocytoclasique, micro-abcès  
et nécrose

- **Biopsie de la muqueuse nasale**

Tissu de granulation inflammatoire

**Diagnostic** : Maladie de Wegener

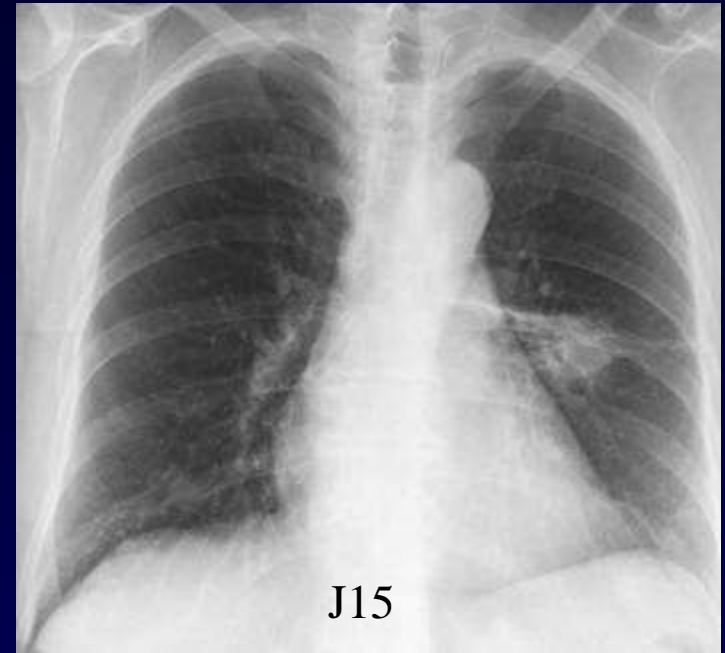
Codage : Poumon - Inflammatoire



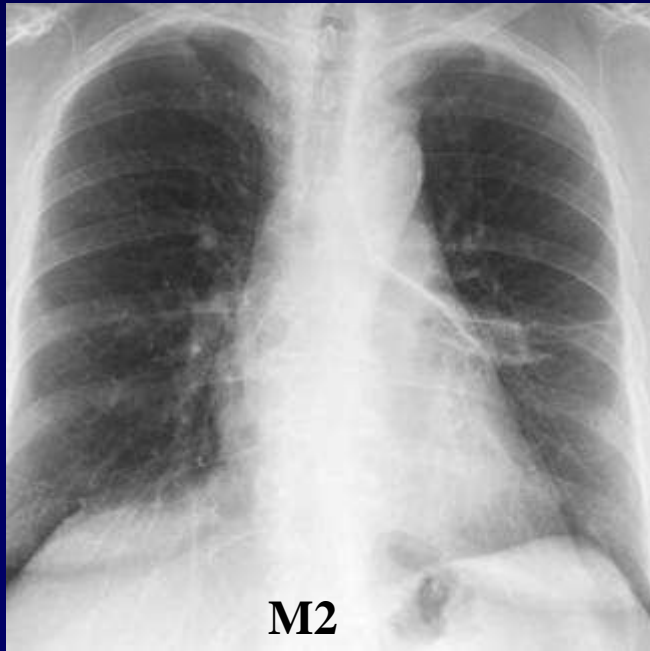
initiale

## Evolution

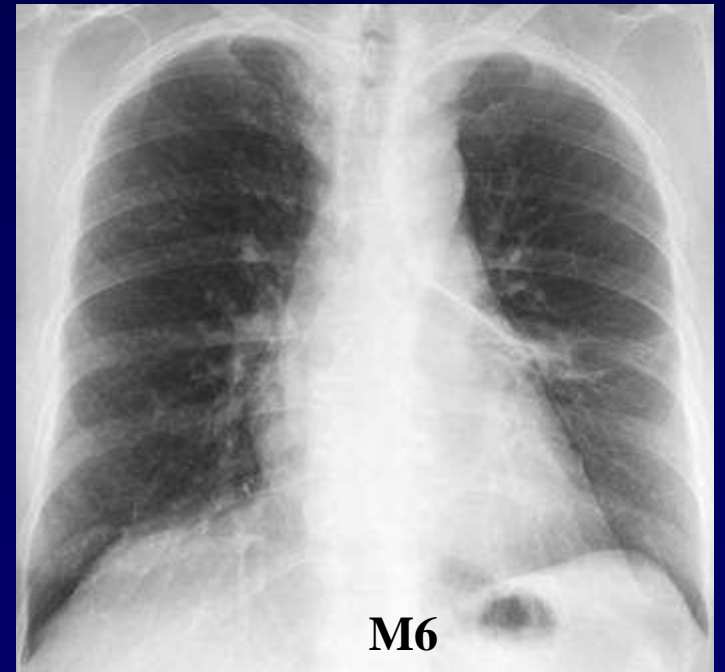
corticoïdes  
+ Endoxan



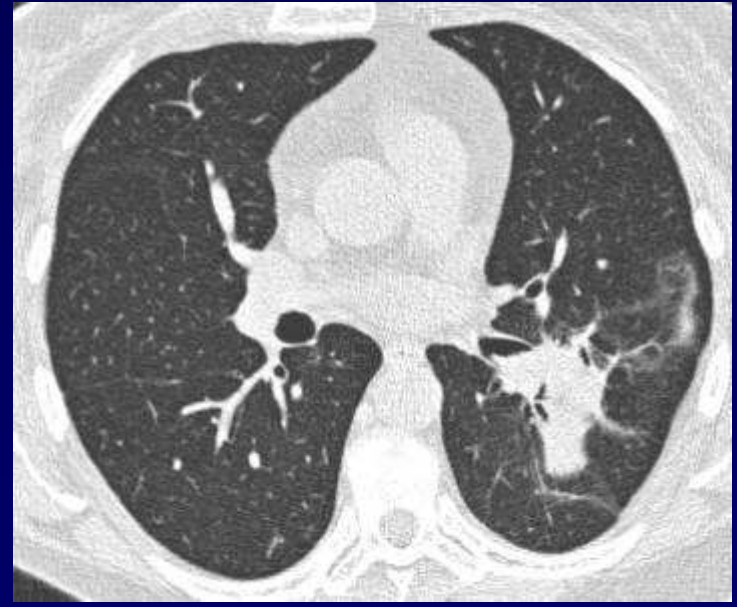
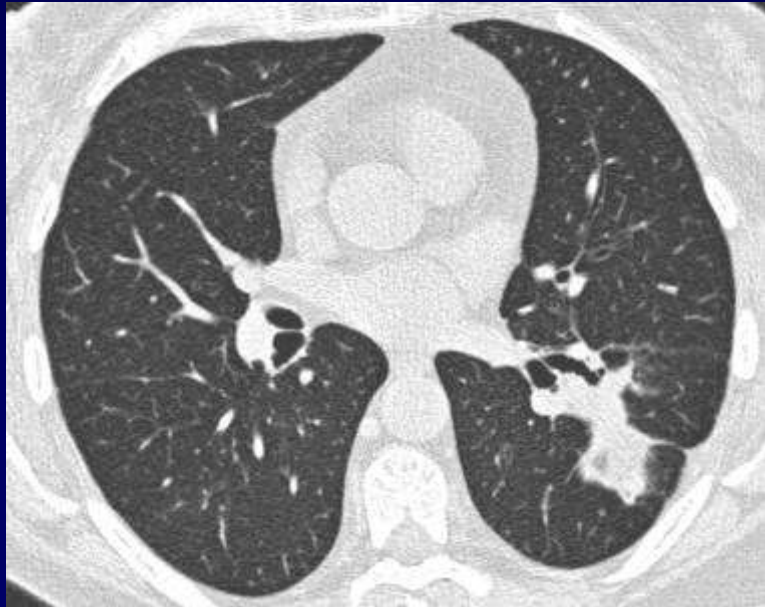
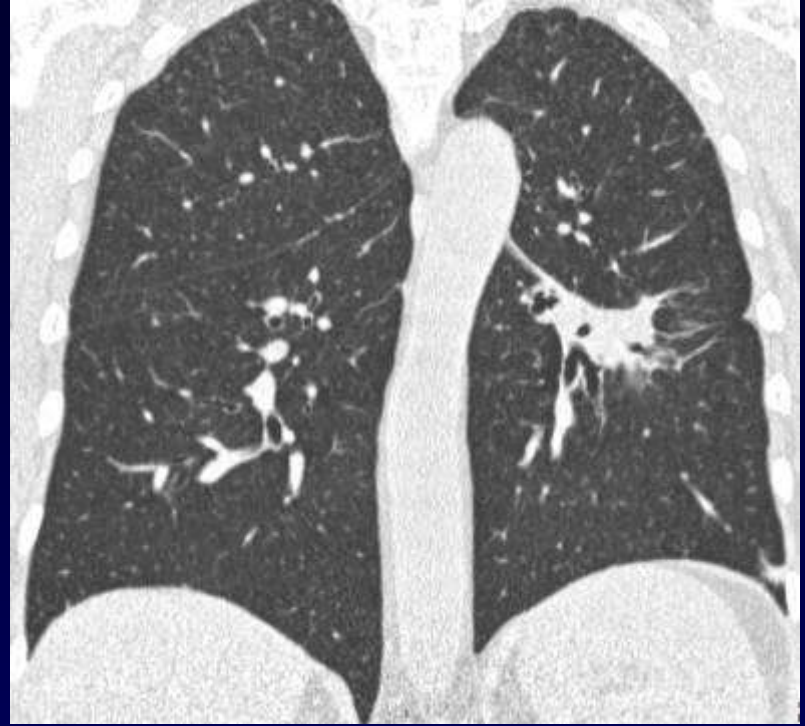
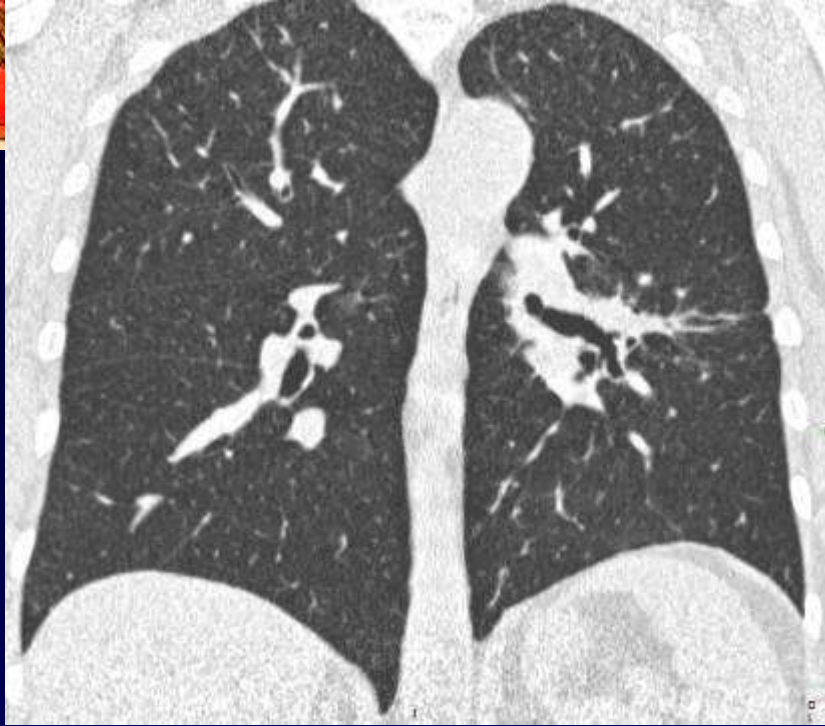J15

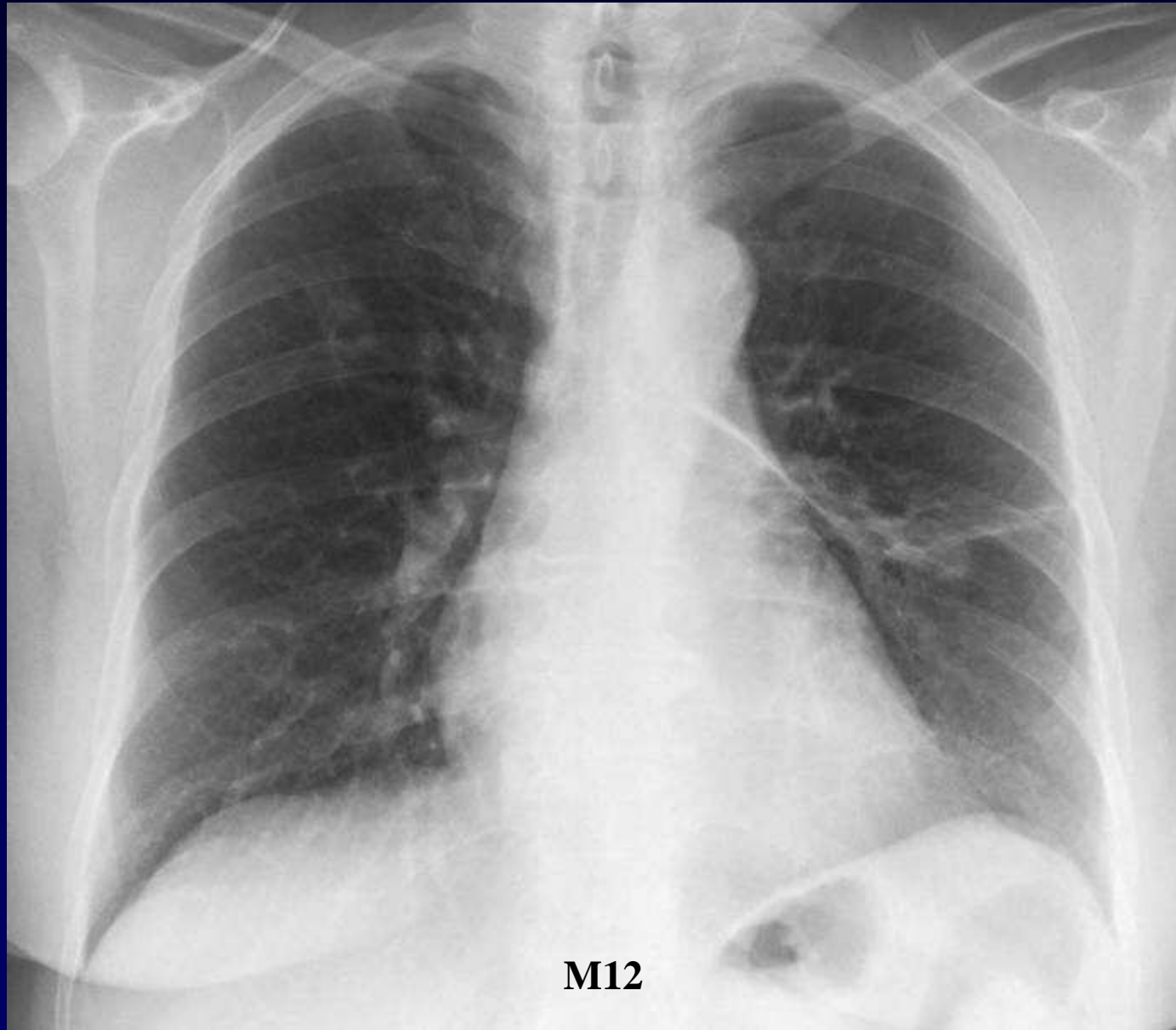


M2



M6





**Toux, crachats hémoptoïques**

